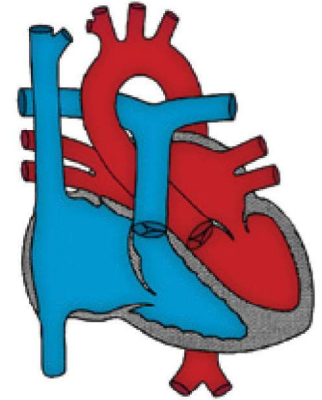
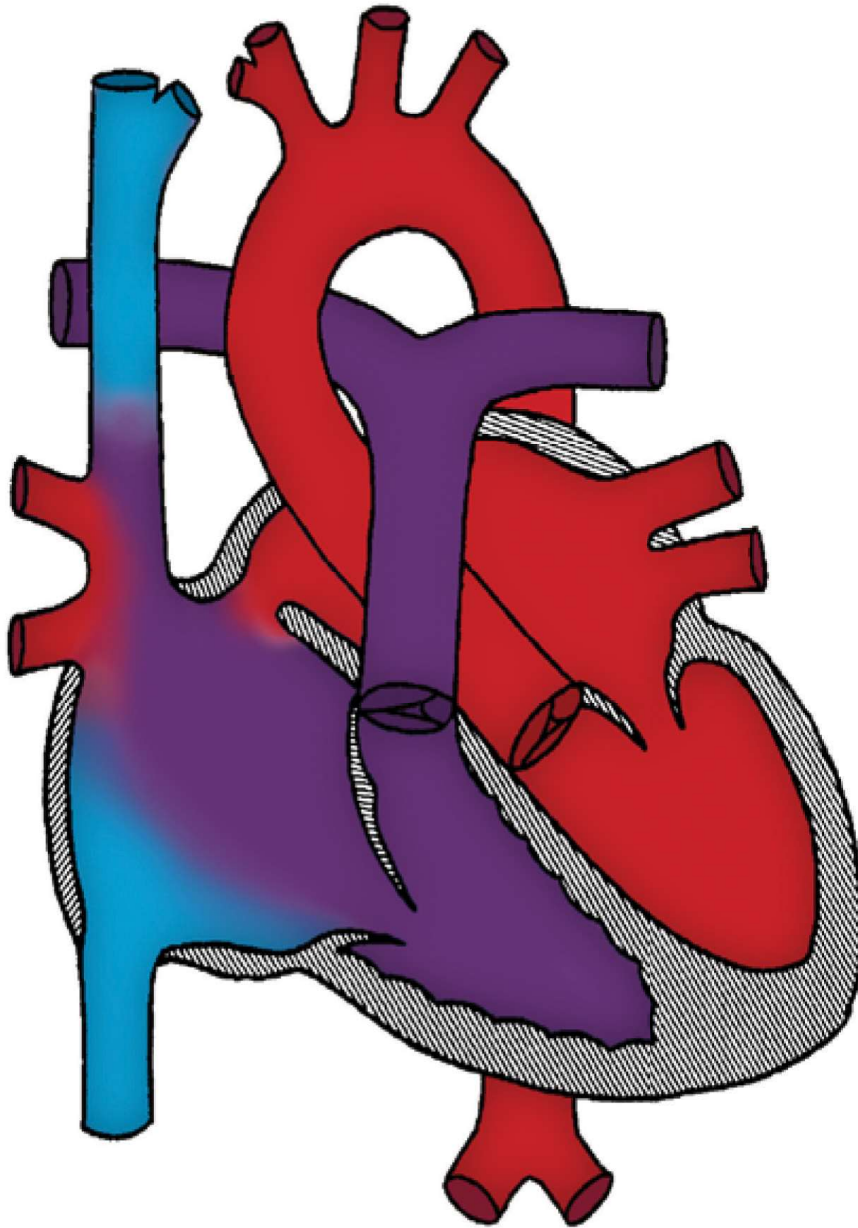




COMMUNICATION INTERAURICULAIRE (SINUS VENOSUS)



Cœur normal